



## Endourology

# Misplacement of DJ stent into inferior vena cava in a patient with retroperitoneal fibrosis, a case report

Amir Reza Abedi<sup>a,\*</sup>, Majid Dargahi<sup>b</sup>, Seyed Jalil Hosseini<sup>a</sup>

<sup>a</sup> Men's Health and Reproductive Health Research Center (IRHRC), Shahid Beheshti University of Medical Sciences, Tehran, Iran

<sup>b</sup> Urology Department, Shohada-e Tajrish Hospital, Shahid Beheshti University of Medical Sciences, Tehran, Iran



## ARTICLE INFO

## Keywords:

DJ stent  
Endovascular migration  
Ureteric stent

## ABSTRACT

Intravascular migration of DJ stent is a rare complication that needs immediate attention to prevent severe complication. We reported a rare case of intravascular migration of DJ stent in a patient with retroperitoneal fibrosis. The DJ stent was removed by cystoscopy with no complication.

## Introduction

DJ stents were introduced in 1967 for the first time in order to relieve ureteral obstruction. Since then, ureteral stents have been used due to different reasons, however stent-related complications are prevalent and can affect the patients' life quality.<sup>1</sup>

Most of these problems including dysuria, hematuria, frequency and stent encrustation are well known but intravascular migration of DJ stent is a rare complication. In this article, we present a patient with retroperitoneal fibrosis in whom DJ stent had been misplaced into inferior vena cava and has been successfully managed with cystoscopy.

## Case presentation

A 75 year old woman was referred to Shohada Tajrish hospital due to three days of hematuria following an insertion of a DJ stent. Her basic HGB was 11 mg/dl that dropped to 9 mg/dl at the time of presentation. She had an earlier history of extensive myocardial infarction two years ago and was diagnosed with retroperitoneal fibrosis a year ago in another medical center and since then, the patient was on Azathioprine and low dose Prednisolone. Due to her bilateral moderate hydronephrosis condition and the serum creatinine of 4mg/dl, bilateral DJ stents were placed by cystoscopy without using fluoroscopy and were exchanged every 3 months. As a result of DJ stent insertion, her serum creatinine decreased to 2 mg/dl. The mentioned patient was on Azathioprine, low dose Prednisolone, ASA 80 mg/daily and Metoral 50mg/daily and Atorvastatin 20 mg/daily. The patient had a history of ITP ten years ago that was managed by Hematologist. The platelet count was in the

normal limit at the time she was referred. Abdominopelvic computed tomography with contrast was scheduled to evaluate the cause of gross hematuria.

Surprisingly the proximal part of DJ stent was seen in the inferior vena cava (IVC) and the distal part was placed in the bladder (Fig. 1). The vital sign of the patient was stable. After discussing the options with the patient, the cystoscopy was scheduled to remove the stent. At the time of cystoscopy, vascular team were kept on standby to explore the patient in the case of bleeding from the IVC. The stent was removed with cystoscopy without any complications. Bilateral nephrostomy was placed because the cardiologist did not allow us to do ureterolysis. The patient's condition was good, three months after the stent removal.

## Discussion

Most patients for whom DJ stents have been placed, complain about problems like frequency, dysuria and hematuria<sup>1</sup> however, intravascular migration of DJ stent is an uncommon complication that was first reported in 2002.<sup>2</sup> It can happen both during open surgery and endourological procedures such as PCNL.<sup>3</sup> If vision is not good during cystoscopy or ureteroscopy or fluoroscopic guidance is not used, DJ Stent might perforate the ureteral wall and adjacent communicating vein and get placed in vascular system and IVC through that vein<sup>4</sup>.

During open surgery, a transected gonadal vein can be mistaken with the ureter,<sup>3,4</sup> in that case the DJ stent may be inserted in the vascular system through the vein. If this happens, significant hematuria can be continued until the vein gets thrombosed. There are several reports about insertion of DJ stent into gonadal vein which has been mistaken

\* Corresponding author.

E-mail address: [amirezabedi@gmail.com](mailto:amirezabedi@gmail.com) (A.R. Abedi).

<https://doi.org/10.1016/j.eucr.2021.101650>

Received 18 February 2021; Received in revised form 16 March 2021; Accepted 17 March 2021

Available online 23 March 2021

2214-4420/© 2021 The Authors.

Published by Elsevier Inc.

This is an open access article under the CC BY-NC-ND license

(<http://creativecommons.org/licenses/by-nc-nd/4.0/>).

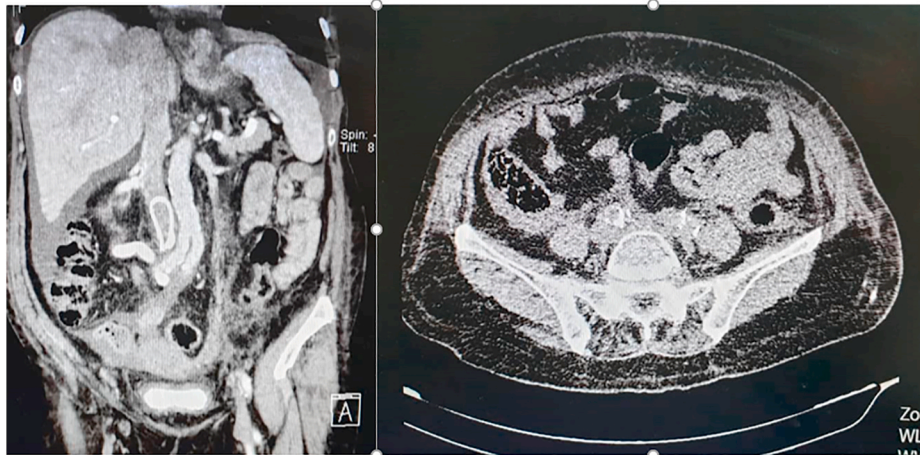


Fig. 1. The proximal coil of DJ stent was located inside inferior vena cava.

with ureter during hysterectomy and boari flap repair.<sup>4</sup>

Three predisposing factors contribute to intravascular migration of DJ stent in the mentioned case:

- First, The ureter was adjacent to gonadal vein and IVC.
- Second, the ureteral wall was flimsy because of chronic inflammation
- Last, the stent insertion was not performed under fluoroscopy.

To prevent intravascular migration of DJ stent, urologist should follow the following strategies:

- First, any resistance felt during insertion of the DJ stent should be taken with extreme caution and the DJ stent should not be forced.
- Second, the length of DJ stents should be proportionate to the height of the individuals that may be anywhere between 26 and 32 cm, and the portion of the DJ stent that is in the renal pelvis and bladder should be at least 180° with the length of >2 cm.<sup>5</sup>
- Third, the warning sign and symptoms such as gross hematuria or severe abdominal pain should be taken into consideration, if so, abdominal CT scan is necessary to confirm the position of the DJ stent.

To prevent complications such as pulmonary embolism, valvular disease and urosepsis, migrated DJs should be removed as soon as possible. Anticoagulant therapy and antibiotic therapy should be started to prevent uropsepsis and thrombotic complication.<sup>5</sup>

Factors that can influence treatment strategies are as follows:

- The location of the stent

- The vital sign of the patient
- The development of thrombus
- The skill of the surgeon.

The treatment options for removal of the DJ stent include:

- Endoscopic surgeries such as cystoscopy or PCNL,
- Laparoscopic procedures,
- Endovascular operation and open surgery.<sup>3-5</sup>

In the above case, cystoscopy was used to remove the DJ stent because of the following reasons:

First, the distal portion of the DJ stent was in the bladder.

Second, we had experienced vascular surgeons on staff.

Third, the patient was stable and there was no retroperitoneal hematoma.

## References

1. Richter S, Ringel A, Shalev M, et al. The indwelling ureteric stent: a 'friendly' procedure with unfriendly high morbidity. *BJU Int.* 2000;85:408–411.
2. Michalopoulos AS, Tzoufi MJ, Theodorakis G, et al. Acute postoperative pulmonary thromboembolism as a result of intravascular migration of a pigtail ureteral stent. *Anesth Analg.* 2002;95:1185–1188.
3. Sabnis RB, Ganpule AP, Ganpule SA. Migration of double J stent into the inferior vena cava and the right atrium. *Indian J Urol.* 2013;29:353–354.
4. Maheshwari PN, Oswal AT, Wagaskar VG. A double J stent misplaced in the inferior vena cava during Boari flap repair Indian. *J Urol.* 2016 Jan-Mar;32(1):71–73.
5. Jiang C, Fu S, Chen J, et al. Migration of a double J stent into the inferior vena cava: a case report. *Medicine (Baltim).* 2019 May;98(20).